
Guided bone regeneration with polypropylene membrane associated with dental implant placement

Regeneração óssea guiada com membrana de polipropileno associada à instalação de implante dentário

Irineu Gregnanin Pedron¹, Luiz Carlos Magno Filho², Munir Salomão³, Felipe Paes Varoli⁴, Mohammed Jasin Al-Juboori⁵

¹Dental School, University Brasil, São Paulo-SP; Brazil; ²Dental School, Funorte, Mogi das Cruzes, Brazil; ³Dental Clinic Private, São Paulo-SP, Brazil; ⁴Dental School, University Brasil and University Paulista, São Paulo-SP, Brazil; ⁵Department of Periodontics, Abrafidaim University College, Bagdá, Iraque.

Abstract

The guided bone regeneration (GBR) technique concept advocates the regeneration osseous defect via the application of occlusive membranes. In fact, what maintains the gingival architecture is the support from the alveolar bone. The regular structure of the osseous-gingival tissue is only possible due to the presence of teeth. The teeth extraction beginning of resorption of the alveolar bone. The resorption is more in width than the height. Angiogenesis and chemotaxis of cells competent for bone formation is only possible with the maintenance of immobility of the clot. Blood cells, particularly platelets, are most responsible for encoding and producing new bone tissue through bone morphogenetic proteins (BMPs), which will repair the post-surgical alveolus. The implant-supported rehabilitations have been prioritized in relation to the use of removable prostheses, thus, alveolar bone preservation is a requirement in daily clinical practice. This case report describes the GBR technique who had use of a polypropylene membrane, demonstration of advantages and should be indicated also for post-surgical alveolus

Descriptors: Bone regeneration; Oral surgery; Bioengineering

Resumo

A técnica de regeneração óssea guiada (ROG) se baseia no conceito de neo-formação óssea por meio da colocação de uma barreira oclusiva sobre um defeito ósseo. Sabe-se que a manutenção da arquitetura ósseo-gengival depende fundamentalmente da presença dos dentes. Após a exodontia, pode ser notada a reabsorção fisiológica no osso alveolar; normalmente, essa perda de massa óssea é notada tanto em espessura como em altura. Porém, com maior prevalência de perda em espessura. Uma das maiores dificuldades em casos envolvendo exodontia é manutenção do coágulo sanguíneo. Particularmente, a manutenção de um coágulo estável é notória para promover a formação óssea mais homogênea no alvéolo residual, diminuindo os índices de remodelação óssea. A utilização de barreiras para promover a manutenção do coágulo é uma situação corriqueira na prática clínica diária, visto que a utilização com implantes dentários tem-se tornado, em muitos casos, a técnica de primeira escolha na reabilitação bucal. O presente relato de caso tem por objetivo apresentar ROG como uma alternativa para a manutenção do coágulo pós exodontia, promovendo a melhor arquitetura ósseo-gengival prévia a instalação do implante dentário.

Descriptors: Regeneração óssea; Cirurgia bucal; Bioengenharia

Introdução

Despite the technical-scientific advances of contemporary dentistry, until today, exodontia is frequent in daily practice. Caries, fractures, periodontal diseases, iatrogenias, unsuccessful therapies, prosthetic failures, persistent pathologies, malocclusions, automobile and / or sports accidents, neglect of oral health, orthodontic indications, among others - all these factors cause dental mutilation¹.

After necessary exodontia, alveolar bone repair begins dynamically. The clot left by the extravasation of blood, after the rupture of the vessels present in the periodontal ligament and the nervous-vascular bundle, carries a series of cellular types, which carry proteins, responsible for genetic information for bone production. The morphogenetic bone proteins, present in blood platelets, signal the primordial sites for the initiation of extracellular matrix mineralization and the subsequent production of the trabecular framework of bone tissue^{2,3}.

Given the rapid colonization of epithelial cells and the expected clot retraction, part of the conical cavity space left after extraction of the dental root will be occupied by epithelial and connective tissue cells. This connective tissue forms a granulation tissue in which there is intense vascular proliferation (angiogenesis), necessary for revascularization and local tissue nutrition. After a few days, the totipotent or pluripotent cells differentiate and the new osteoblasts, as well as the existing ones, secrete a matrix that can mineralize^{4,5}.

The guided bone regeneration technique seeks, through a physical barrier, the containment of cell types undesirable to the alveolar bone repair, favoring the immobility of the osteoblasts in the proliferative alveolar site. The osteoblasts, precursors of bone tissue, can emit pseudopodia by installing and initiating the process of secretion of the extracellular matrix that will later mineralize. From osteoid tissue to maturation, in a few months, it will culminate in the formation of concentric

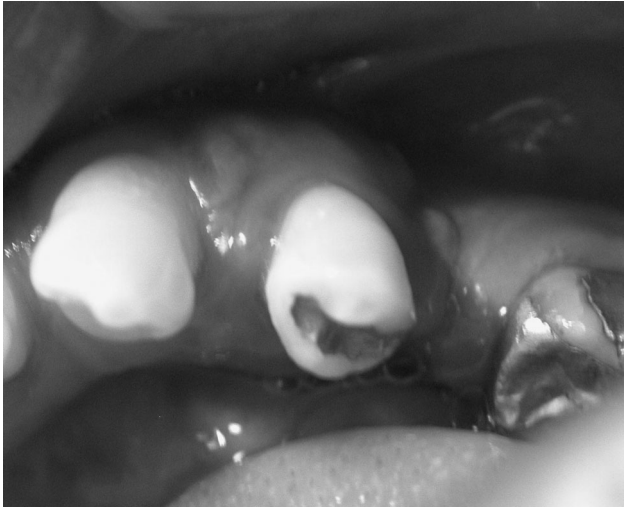

Figure 1. Initial clinical features: generalized chronic periodontitis and pathologic migration on tooth 44

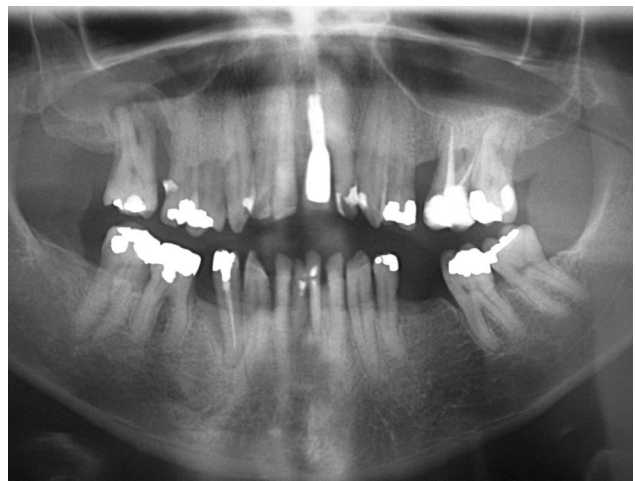

Figure 2. Panoramic radiograph showed dental losses and generalized bone loss in alveolar ridges

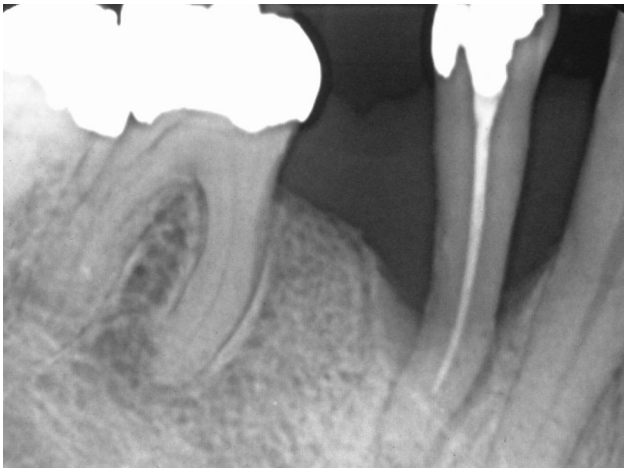

Figure 3. Periapical radiograph showed bone loss on tooth 44

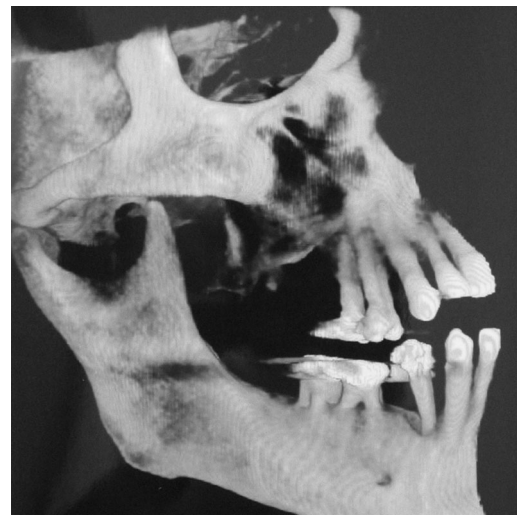

Figure 5. 3D Reconstruction from computed tomography showing bone loss in tooth 44

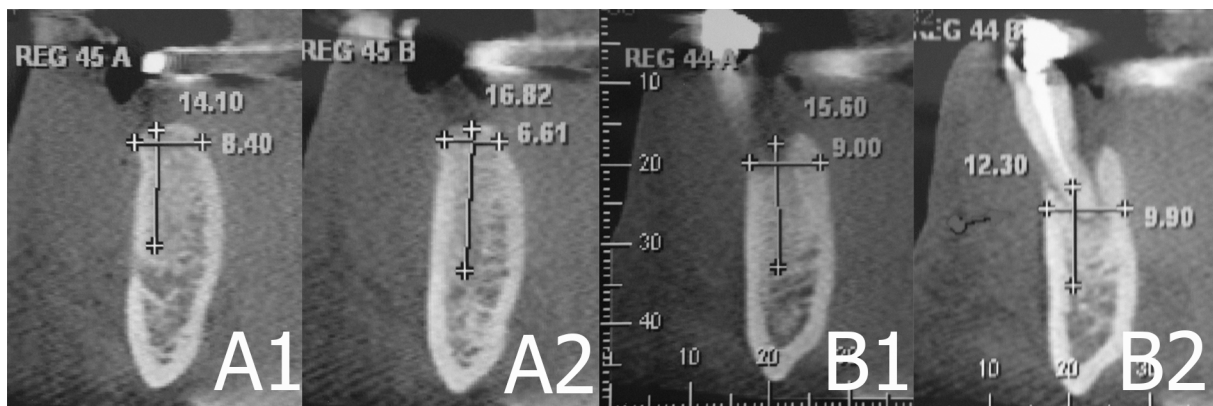


Figure 4. Remaining bone on tooth 44 (computed tomography - cross sections)

lamellae, with Havers and Volkmann channels, with adequate nutrition, which makes the tissue susceptible to the maintenance of the functional activities resulting from masticatory loads, provided that it is made detailed prosthetic rehabilitation with satisfactory reverse planning⁶. Several materials were tested and used as a barrier, among them: castor, polytetrafluoroethylene and even gold screens⁷. However, the results achieved were conflicting and little accessible to daily clinical practice^{8,9}.

The purpose of this paper is to present a case of the use of polypropylene membrane post-exodontia, with perspective of future dental implant placement and prosthetic rehabilitation.

Case Report

A black male patient, 54 years-old, attended the private clinic with a need for periodontal treatment and exodontia.

Clinically, generalized chronic periodontitis was observed, with marked mobility and pathologic migration on tooth 43 (Figure 1).

Radiographs showed dental losses (teeth 16, 18, 21, 25, 28, 35, 36, 45 and 48), dental implant (tooth 21), generalized horizontal bone loss in alveolar ridges and marked vertical bone loss and angled root in tooth 44 (Figures 2, 3, 4 and 5).

Periodontal treatment was performed and tooth extraction 44 was indicated. However, with the future prospect of implants and prostheses placement, the use of regenerative techniques (Guided Bone Regeneration) was suggested. After the patient's consent, the use of the polypropylene membrane was recommended.

After the exodontia, with subsequent curettage of the lesions and abundant irrigation with saline solution, the polypropylene membrane (Bone Heal®, INP, São Paulo, Brazil) was cut, adapted, inserted and sutured (Figure 6). The membrane was intentionally exposed to the buccal medium (Figure 6C). Analgesic, anti-inflammatory and antibiotic drugs were administered post-surgically.

At 10 postoperative days, the remaining sutures and membrane were removed. No postoperative changes or complications were observed or reported. Clinically, maintenance and immobilization of the clot were observed, maintaining relative thickness of the alveolar ridge.

After 6 months (Figure 7), the placement of implant and prosthetic rehabilitation (Figures 8, 9 and 10) were performed. The patient has been accompanied in periodontal and implant programme of maintenance.

Discussion

In the post-exodontia period, there is physiological and determinant coagular retraction, originating from the salivary enzymes and from the indigenous microbiota of the oral cavity itself. Local hemostasis initiates a series of cellular and tissue phenomena common to physiological repair¹⁰. The fibrin screen interconnects the walls of the alveolus, giving a yellowish and gelati-

nous appearance to the site. First-line cells of organic or immune defense, like neutrophils, try to prevent the invasion of bacteria from the buccal environment. Salivary immunoglobulins and epithelial growth factors also aid in the neutralization of these invading microorganisms².

The endosteum and the periodontal ligament, three days after the surgical act, provide differentiated and undifferentiated cells, contributing greatly to the cellular colonization of the granulation tissue that forms towards the center of the alveolar cavity left after the exodontia^{1,3}.

Four days after the procedure, malformed trabeculae of primordial bone fill the defect. Its restricted function confers only a filling without intending to undergo more intense mechanical efforts, such as more vigorous mastication^{11,12}.

At seven days, angioblastic proliferation forms in the alveolar center, and in the osseous cortical walls, mature or secondary bone tissue interposes to the granulation tissue^{2,3}.

At three weeks, there is complete isolation between the postoperative alveolus and the oral cavity. In the apico-cervical sense there is formation of secondary bone. Up to 35 days, new osteoblasts are formed from osteoprogenitor cells, with osteoid tissue being secreted. At 45 days, connective tissue permeated by mature bone tissue with irregular trabeculae is formed. Osteocytes are trapped in the adult bone tissue that formed¹³.

At just 4 months, bone tissue is considered morphologically compatible with more severe mechanical stresses and consistent with the onset of more reliable prosthetic rehabilitation. Normally, the expectant time of 4 months for the maxilla and 6 months for the mandible are necessary after the surgical act for the planning of implant-supported rehabilitations¹⁴. Even the execution of pre-prosthetic surgeries requires planning based on a terminal bone maturation^{15,16}.

The importance of the immobility of the clot in the alveolar bone rehabilitation after the surgical procedure is emphasized. Thus, bone sequestration, restorative material remains, surgical wound infections, abrupt increases in local temperature above 47° C for a time greater than 1 minute (causing protein denaturation and minimization of alkaline phosphatase), untimely movements of the flap or traumatic removal of sutures, among others, postpone correct alveolar repair¹⁷.

Autogenous bone grafts are considered the gold standard in cases of necessary replacement and filling of sites whose loss was inexorable. Bone substitutes have been developed with the purpose of saving surgical time and of not requiring the need for a second surgical stage with greater morbidity for the patient²⁴⁻²⁷. Membranes or screens have made it possible to maintain the grafts in position, since the periosteum does not always reach adequate containment due to extensive bone defects. Surgeries of maxillary sinus removal, correction of bone defects due to traumas or periodontal problems, augmentation of aesthetic areas after extraction or periodontal surgeries with connective tissue grafts and apposition of blocks or particles of autoge-

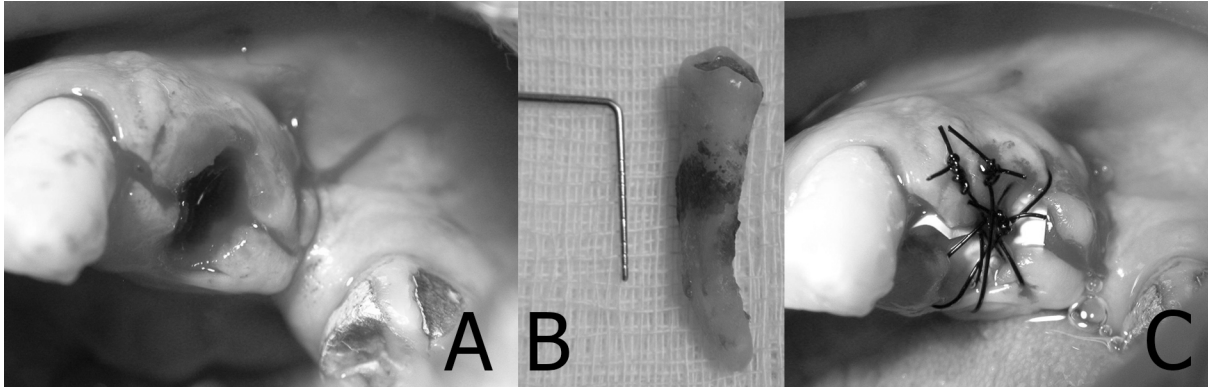


Figure 6. Immediate post-exodontic surgical bed (A). Tooth 13 removed, presenting angled root (B). Polypropylene membrane exposed to the buccal medium and sutured on the postoperative surgical bed (C)

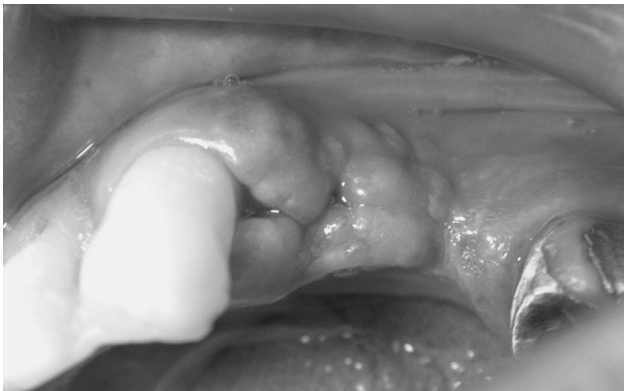

Figure 7. Post-surgical (6 months) after exodontia

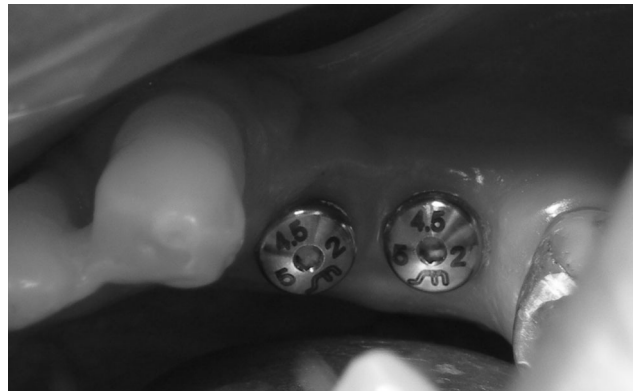


Figure 8. Installation of osseointegrated implants

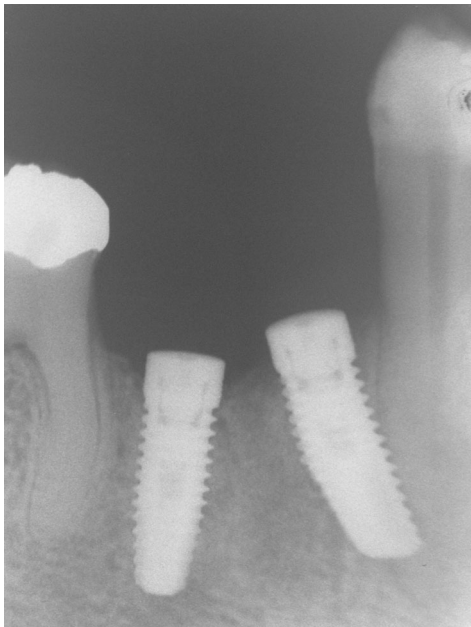

Figure 9. Installation of osseointegrated implants (periapical radiograph)

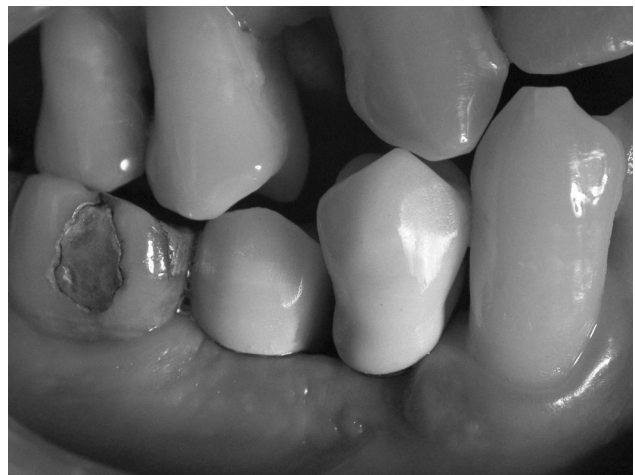

Figure 10. Prosthetic rehabilitation performed

nous bone use the membranes or barriers as a means aids in bone repair²⁸⁻³⁰.

Membranes of various types of material have been employed in the technique of guided bone regeneration. We look for a set of characteristics, considered ideal for the use of these barriers: being able to be cut and shaped; easy adaptability; mechanical resistance compatible with applied loads; malleability; low cost; unnecessary additional resources such as bolts or tacks; possible exposure to the oral environment without promoting infection; unnecessary relaxing incisions; and possible removal without the use of drill bits or punch instruments. The polypropylene membrane, in the presented case, fulfilled the majority of the desired requirements and fulfilled the task of osteopromotion¹⁸.

The polypropylene membrane potentially has numerous advantages, such as: intentional exposure of the membrane to the buccal environment; the flaps may be kept apart from each other pending healing by second intention; there is no supremacy of use of granular biomaterials within the alveolus, only blood clot; without greater financial expenditures with complementary instruments; without previous hydration, being dimensionally stable during the period of stay in the surgical niche; being waterproof; it can be removed between 7 and 14 days; without adherence to scar tissue; the inner surface promotes adsorption of osteoblasts and precursor cells; it can be used in cases of immediate implants by the Schroeder Technique with also immediate load, allowing the simultaneous regeneration of bone and inserted gingiva tissue; hindering the accumulation of dental biofilm and food debris¹⁹⁻²³.

Within the scope of contemporary dentistry, which prizes for maximum preservation and minimal intervention, the guided bone regeneration technique with membrane aid is considered as an effective alternative in osteopromotion and osteogenesis. The barrier selectivity characteristic, by histologically competent cells for the production of bone tissue, in the region of the post-extraction alveolus, protects the clot, potentiates the local physiology and cares for greater contribution in the reverse planning, aiming at the more reliable prosthetic rehabilitation and promising, with better prognosis and longer longevity²⁷⁻²⁸.

Conclusions

The potentiation of alveolar bone repair through guided bone regeneration concentrates the basis of the osteopromotion phenomenon. Thus, treatments of periodontal defects, alveolar sites after dental extractions, maxillary sinus lift and desired increases of the alveolar ridge are common clinical-surgical procedures in which guided bone regeneration is employed. The practice of using bone substitutes and allogeneic, xenogenic and alloplastic grafts requires longer clinical time and greater cost for the patient. The physico-chemical characterization of these bone substitutes provides incomprehensible parameters, such as: crystallinity, contact surface and compositional constitution. These factors lead to

loss of control of bone repair rates as well as the amount of degradation of these biomaterials over time. More predictable treatment options, with lower morbidity for the patient, with consequent reduction of costs, are required.

References

1. Puricelli E. Técnica anestésica, exodontia e cirurgia dentoalveolar. 1.ª ed, São Paulo: Artes Médicas. 2014.
2. Consolaro A. Reparação óssea, alveolar e peri-implantar: compreendendo a osseointegração! In: Consolaro A. Inflamação e reparo. 2.ª ed; DentalPress; 2015.
3. Marzola C, Abreu EM. Processos de reparo alveolar. In: Marzola C. Técnica exodôntica. 2.ª ed; Pancast. 1994; 303-26.
4. Araújo MG, Sukekava F, Wennström JL, Lindhe J. Tissue modeling following implant placement in fresh extraction sockets. Clin Oral Implants Res. 2006;17(6):615-24.
5. Araújo MG, Wennström JL, Lindhe J. Modeling of the buccal and lingual bone walls of fresh extraction sites following implant installation. Clin Oral Implants Res. 2006;17(6):606-14.
6. Schropp L, Wenzel A, Kostopoulos L, Karring T. Bone healing and soft tissue contour changes following single-tooth extraction: a clinical and radiographic 12-month prospective study. Int J Periodontics Restorative Dent. 2003;23(4):313-23.
7. Salomão M, Cunha J, Morales RJ, Siqueira JTT. Regeneração óssea guiada com barreira de polipropileno intencionalmente exposta ao meio bucal. Rev Catarinense Impl. 2012;12(1):65-8.
8. Salomão M, Tessare Junior PO, Fonseca MB. Caso clínico - Regeneração óssea guiada utilizando barreira de polipropileno (BoneHeal®), associado a enxerto xenógeno (BIO-OSS®) e enxerto de tecido conjuntivo, otimizando a reabilitação com implante dental. Rev Catarinense Impl. 2016;18(1):42-4.
9. Borges FL, Dias RO, Piattelli A, Onuma T, Cardoso LAG, Salomão M, et al. Simultaneous sinus membrane elevation and dental implant placement without bone graft: A 6-month follow-up study. J Periodontol. 2011;82(3):403-12.
10. Salomão M, Alvarez FK, Siqueira JTT. Regeneração óssea guiada em defeitos extensos pós-exodontias utilizando membrana exposta ao meio bucal. Rev ImplantNews. 2010;7(6):753-9.
11. Salomão M, Siqueira JTT. Uso de barreira de polipropileno pós exodontia. Relato de três casos clínicos. Rev Bras Impl. ant. 2009;15(1):12-5.
12. Salomão M, Siqueira JTT. Regeneração óssea guiada através de barreira exposta ao meio bucal após exodontias. Rev Bras Impl. ant. 2010;16(1):5-7.
13. Lacerda EJR, Lacerda HM, Salomão M. Invaginação de tecido conjuntivo após levantamento do seio maxilar, uso de biomateriais e implante tardio: resolução cirúrgica em um caso clínico. Rev ImplantNews. 2012;9(6):843-50.
14. Ley J. Minimally invasive extraction and immediate implant placement: the preservative. J Oral Impl. 2006;32(4):204-5.
15. Schropp L, Kostopoulos L, Wenzel A. Bone healing following immediate versus delayed placement of titanium implants into extraction sockets: a prospective clinical study. Int J Oral Maxillofac Implants. 2003;18(2):189-99.
16. Botticelli D, Berglundh T, Lindhe J. The influence of a biomaterial on the closure of a marginal hard tissue defect adjacent to implants: an experimental study in the dog. Clin Oral Implants Res. 2004;15(3):285-92.

17. Nemcovsky CE, Moses O. Rotated palatal flap. A surgical approach to increase keratinized tissue width in maxillary implant uncovering: technique and clinical evaluation. *Int J Periodontics Restorative Dent*. 2002;22(6):607-12.
18. Salama M, Ishikawa T, Salama H, Funato A, Garber D. Advantages of the root submergence technique for pontic site development in esthetic implant therapy. *Int J Periodontics Restorative Dent*. 2007;27(6):521-7.
19. Carvalho PSP, Ponzoni O, Bassi APF. Manutenção de volume do processo alveolar após exodontia com raspa de osso cortical autógeno. *Rev ImplantNews*. 2004;1(1):53-8.
20. Lacerda EJR, Lacerda HM. Regeneração óssea guiada por meio de membrana não-absorvível pós-exodontia. *Rev Implant-News*. 2010;7(1):87-92.
21. Sohn D, Moon J, Lee W, Kim S, Kim C, Kim K, Moon Y. Comparison of new bone formation in the maxillary sinus with and without bone grafts: immunochemical rabbit study. *Int J Oral Maxillofac Implants*. 2011;26(5):1033-42.
22. Garcia RP, Ferezin PHV, Kfourri FA. Manutenção alveolar pós-exodontia com membrana de polipropileno e fibrina rica em plaquetas e leucócitos (L-PRF). *Rev Paul Odontol*. 2017;40(1):18-23.
23. Salomão M, Siqueira JTT. Recuperação do rebordo alveolar através de barreira exposta ao meio bucal. Novo paradigma? *Rev Catarinense Implant. dent*. 2010;10(1):26-8.
24. Salomão M, Siqueira JTT. Uso de barreira exposta ao meio bucal para regeneração óssea guiada após exodontia. *Rev Assoc Paul Cir Dent*. 2010;64(3):184-8.
25. Zeppini LAS. Barreira de polipropileno - Uma nova abordagem para regeneração óssea guiada (ROG). *Rev Odontol (ATO)*. 2014;14(5):301-7.
26. Silva BCR, Salomão M, Siqueira JTT. Regeneração de defeito ósseo extenso pós-exodontia para instalação de implante osteointegrável com uso de barreira intencionalmente exposta ao meio bucal. Relato de caso. *Rev Catarinense Impl*. 2013;13(1):54-7.
27. Caplanis N, Lozada JL, Kan JYK. Extraction defect: assessment, classification and management. *J Calif Dent Assoc*. 2005;33(11):853-63.
28. Nevins M, Camelo M, De Paoli S, Friedland B, Schenk RK, Parma-Benfenati S, et al. A study of the fate of the buccal wall of extraction sockets of teeth with prominent roots. *Int J Periodontics Restorative Dent*. 2006;6(1):19-29.
29. Fickl S, Zuhr O, Wachtel H, Stappert CFJ, Stein JM, Hürzeler MB. Dimensional changes of the alveolar ridge contour after different socket preservation techniques. *J Clin Periodontol*. 2008;35(10):906-13.

Corresponding author:

Irineu Gregnamin Pedron
Rua Flores do Piauí, 508
São Paulo-SP, CEP 08210-200
Brasil

E-mail:igpedron@alumni.usp.br

Received October 2, 2018
Accepted November 14, 2018